Current Cardiology Reports (2026) 28:12
https://doi.org/10.1007/s11886-025-02327-3

ECHOCARDIOGRAPHY (JM GARDIN AND AH WALLER, SECTION EDITORS)

Echocardiography in Athletes: the Ever-Evolving Assessment of Physiology Versus Pathology

John T. Fritzlen[1] · Matthew W. Martinez[2]

Received: 17 October 2025 / Accepted: 11 November 2025
© The Author(s) 2025

Abstract

Purpose of Review This review article summarizes the established physiologic adaptations seen on echocardiogram in athletes and provides a focus update and perspective on changing diagnostic criteria in several pathologies known to overlap with exercise induced cardiac remodeling.

Recent Findings There have been recent publications regarding improved diagnostic criteria for apical hypertrophic cardiomyopathy, shift towards "excessive trabeculations" rather than historically termed non-compaction, and expanding knowledge of arrhythmogenic cardiomyopathies. Exercise induced cardiac remodeling can be mistaken for these pathologies, among others.

Summary As the evaluation of cardiomyopathies changes with the growing understanding of the pathology, it is important that these updates are compared to the potential physiologic adaptation seen in athletic training. It is imperative for the practicing cardiologist to remain knowledgeable of these evolving guidelines.

Keywords Exercised induced cardiac remodeling · Athlete · Left ventricular contractile reserve · Apical hypertrophic cardiomyopathy · Excessive trabeculations · Arrhythmogenic cardiomyopathy

Abbreviations

ApHCM	apical hypertrophic cardiomyopathy
ARVC	arrhythmogenic right ventricular cardiomyopathy
CT	computed tomography
DCM	dilated cardiomyopathy
ECG	electrocardiogram
EICR	exercise induced cardiac remodeling
FAC	fractional area of change
GLS	global longitudinal strain
HCM	hypertrophic cardiomyopathy
LAScd	left atrial conduit strain
LASr	left atrial reservoir strain
LV	left ventricle
LVEDD	left ventricular end diastolic dimension
LVEF	left ventricular ejection fraction
LVH	left ventricular hypertrophy
MRI	magnetic resonance imaging
MWT	maximum wall thickness
PLAX	parasternal long axis
RV	right ventricle
RVEF	right ventricular ejection fraction
RVOT	right ventricular outflow tract
SAX	short axis
TAPSE	tricuspid annular plane systolic excursion

✉ Matthew W. Martinez
matthew.martinez@atlantichealth.org

[1] University of Kansas Medical Center, 3901 W. Rainbow Blvd, Kansas City, KS 66160, USA

[2] Atlantic Health, 111 Madison Ave Morristown, 07960, NJMorristown, USA

Introduction

The physiologic adaptations the heart can undergo with long-term athletic training have been well established. As the limits of physical achievement are continually advanced, it can be challenging to discern exercise induced cardiac remodeling (EICR) from pathologic changes. The assessment of an athlete's heart begins with understanding the potential adaptations specific to the sport and position the athlete plays, as well as inherent factors such as sex, race, and co-existing comorbid conditions. The recently published

Published online: 17 January 2026

Clinical Considerations for Competitive Sports Participation for Athletes with Cardiovascular Abnormalities modify the previous sports participation classification schema from the traditional "static vs. dynamic" to a "strength vs. endurance" continuum, though the underlying physiological adaptations remain unchanged [1]. Athletes with primarily endurance training are more apt to develop cardiac chamber dilation compared to those athletes with primarily strength training who develop relative hypertrophy. In examining sex-based differences, there are separate standard chamber dimensions, left ventricular mass indexes, and aortic dimensions for males and females. Female athletes are also less likely to develop concentric hypertrophy [2]. Racial differences have also been described with a higher prevalence of left ventricular hypertrophy among black athletes compared to non-black athletes. The master athletes may have coexisting medical conditions such as hypertension which can further cloud the distinction between EICR and pathology. All these factors must be considered when interpreting an athlete's echocardiogram.

Echocardiography is the first line imaging modality for the secondary assessment of athletes with concerning family history, abnormal electrocardiogram (ECG), or cardiovascular symptoms. Echocardiography is non-invasive, mobile, non-radiating, and less expensive than computed tomography (CT) and magnetic resonance imaging (MRI). Image acquisition is dependent on sonographer expertise and can be affected by patient factors. Visualization of certain structures such as the left ventricular apex, right ventricle, or coronary arteries can be limited. Echocardiography lacks the tissue characterization of cardiac MRI and spatial resolution of CT. Thus, the use of advanced cardiac imaging may ultimately be required to discern physiology from pathology as an adjunct to echocardiography [3, 4].

The Left Ventricle

The left ventricle (LV) may initially be assessed for the presence and pattern of hypertrophy. The generally accepted value for increased wall thickness begins at 12 mm though athletes have demonstrated physiologic remodeling with LV wall thickness of 13–15 mm. This has been described as the "gray zone" in which pathologic changes should be considered [5]. Beyond 15 mm, secondary causes of left ventricular hypertrophy (LVH) are more likely and require further evaluation. The accuracy of each measurement should be routinely scrutinized as the evaluation of basal septal hypertrophy can be challenging due to incorporation of right ventricular structures such as the crista supraventricularis as shown in Fig. 1. Using biplane at the basal septum or reviewing the short axis view of the basal septum, should be performed to confirm ventricular wall measurements.

The normal myocardium tapers as it reaches the apex. The lack of tapering may represent relative hypertrophy in apex despite absolute wall thickness < 15 mm and that an indexed thickness to the normative apical wall thickness has been proposed to improve diagnostic confidence of apical hypertrophic cardiomyopathy (ApHCM). A ratio less than 1 is suggestive of ApHCM [6]. CMR has permitted the recognition and understanding that relative ApHCM shares many similar morphologic features with ApHCM. Cardiologists in practice integrate imaging (maximum wall thickness (MWT), lack of apical tapering, apical cavity obliteration, presence, and pattern of fibrosis), with or without genetic information to make a diagnosis as depicted in Fig. 2. MWT is typically a nonindexed value, recent studies found that indexing to body size improved accuracy for diagnosis of relative ApHCM patients correctly classified. This method improved the diagnostic accuracy compared with the previous apical: basal ratio model from 59% to78%. As alluded to, there can be racial differences in hypertrophy and athletic adaptations. In a study by Kim et al., they examined black and white athletes playing collegiate American football, separated by position to linemen and non-linemen. They found that concentric left ventricular hypertrophy was more common in black non-linemen athletes (24%) compared to white non-linemen athletes (8%) at the conclusion of the 3-year study. There were similar rates of concentric hypertrophy in both black and white linemen [7]. Thus, the athlete history and the pattern of hypertrophy is an important finding as asymmetrical hypertrophy or apical hypertrophy is more consistent with pathology such as hypertrophic cardiomyopathy (HCM). Left ventricular cavity size has been shown to assist with the discrimination of EICR and HCM with a left ventricular end diastolic dimension (LVEDD) < 51 mm offering greater specificity for HCM [8]. The specificity increases further with decreasing LVEDD but loses sensitivity. Athletes with HCM have demonstrated the ability to remodel and undergo LV dilation. In cases in which pathology is considered, additional imaging with cardiac MRI may be warranted for accurate chamber assessment.

Left ventricular dilation is an expected physiologic adaptation in endurance athletes and will commonly be found on echocardiography. The published upper limit of left ventricular LVEDD for the male adults is 58 mm and for adult females is 52 mm [9]. However, several studies examining LVEDD in athletes undergoing endurance training and combined endurance and strength training found maximum dimensions up to 68–70 mm [3]. As such, the distinction between pathology and physiology is not clear and the assessment of spherical index can be useful. While there may not be an exact established cutoff, the greater the

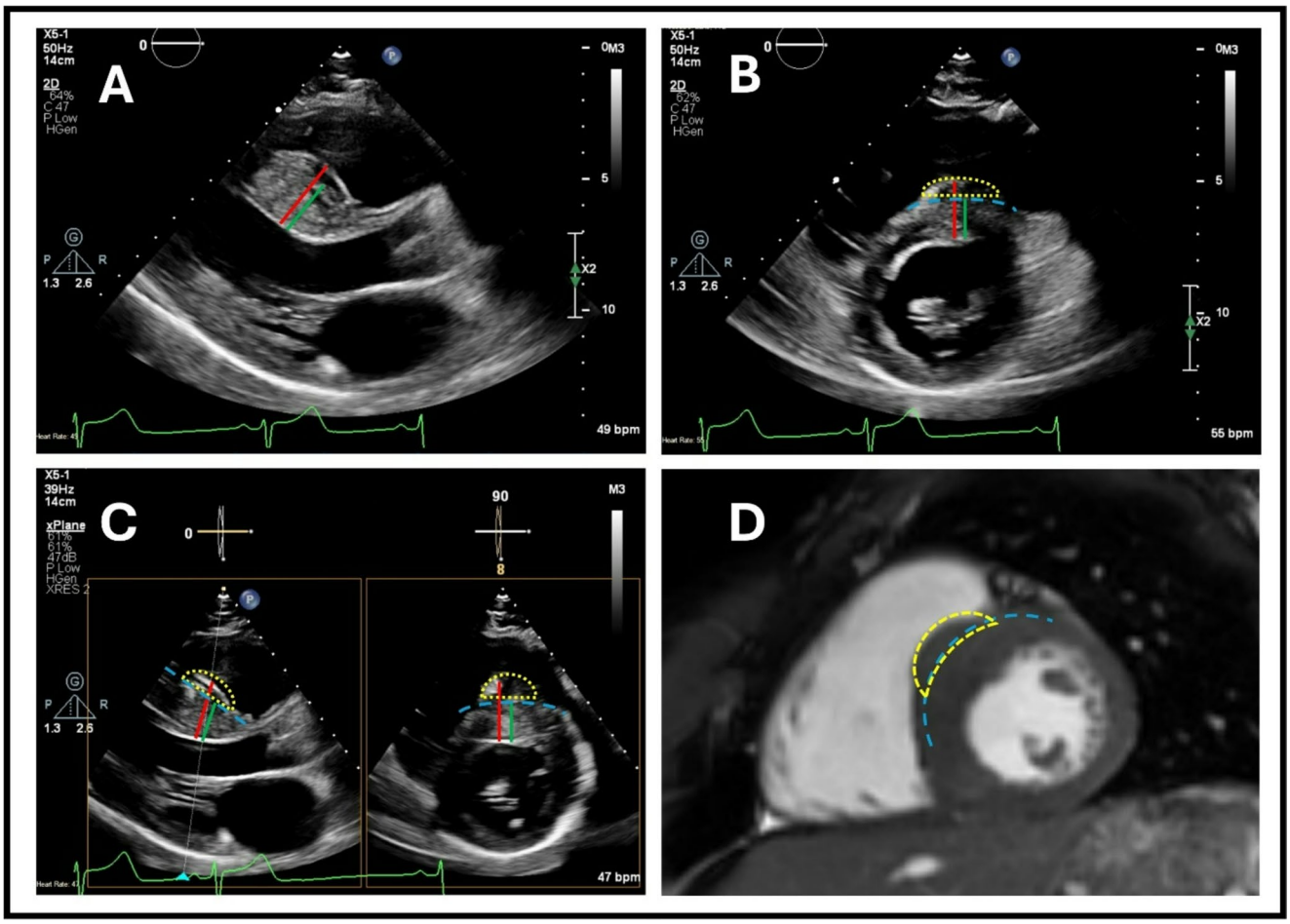

Fig. 1 The 2D echocardiogram image in panel A obtained in the parasternal long axis view shows the basal anteroseptal wall segment. The red line demonstrates an overmeasurement of the basal septal wall thickness by including the crista supraventricularis. The green line is correct measurement of the basal septal wall. In the short axis view seen in panel B, the distinction between the left ventricle and right ventricle is clearer and marked by the blue dashed line. The crista supraventricularis is outlined in yellow. Panel C demonstrates how the use of biplane can assist with confirming findings on standard parasternal long and short axis, Panel D is an image taken from cardiac MRI showing the crista supraventricularis outlined in yellow

spherical index, the greater the suspicion for pathologic remodeling. In a recent study of patients with nonischemic dilated cardiomyopathies, a 3-dimensional spherical index (3D-SI) of ≥0.62 was found to have significantly worse outcomes [10]. Relative increase in LV dilation compared to RV dilation should also be noted as athletes participating in endurance training will experience similar increase in both chambers and potentially even greater increase in RV size with higher levels of training [11, 12]. Quantitative assessment is challenging given visualization of right ventricle's complex structure and the degree of exercise induced cardiac remodeling that can occur. Thus, a qualitative comparison of chamber sizes on echocardiography is often the initial assessment and further imaging with cardiac MRI may be warranted. In the setting of valvular abnormalities such as aortic insufficiency, there may be dilation due to volume load in addition to EICR. Careful consideration of each's contribution must be weighed in the management of these athletes. In certain cases, a period of detraining over several months, followed by repeat echocardiogram to reassess chamber dimensions, can be considered, especially if surgery may be required; however, there is limited data on whether detraining has predictable results for reversing features of athletic training.

Left ventricular systolic function typically remains preserved though mild reduction in left ventricular ejection fraction (LVEF) can occur. In the setting of exercised induced cardiac remodeling and left ventricular dilation, left ventricular end diastolic volume increases. As compensation, a lower ejection fraction can maintain adequate stroke volume and cardiac output under resting conditions. Studies have shown decreases in LVEF to approximately 45% with LVEF < 45% raising concerns for cardiomyopathy [13, 14]. The coexistence of segmental wall motion

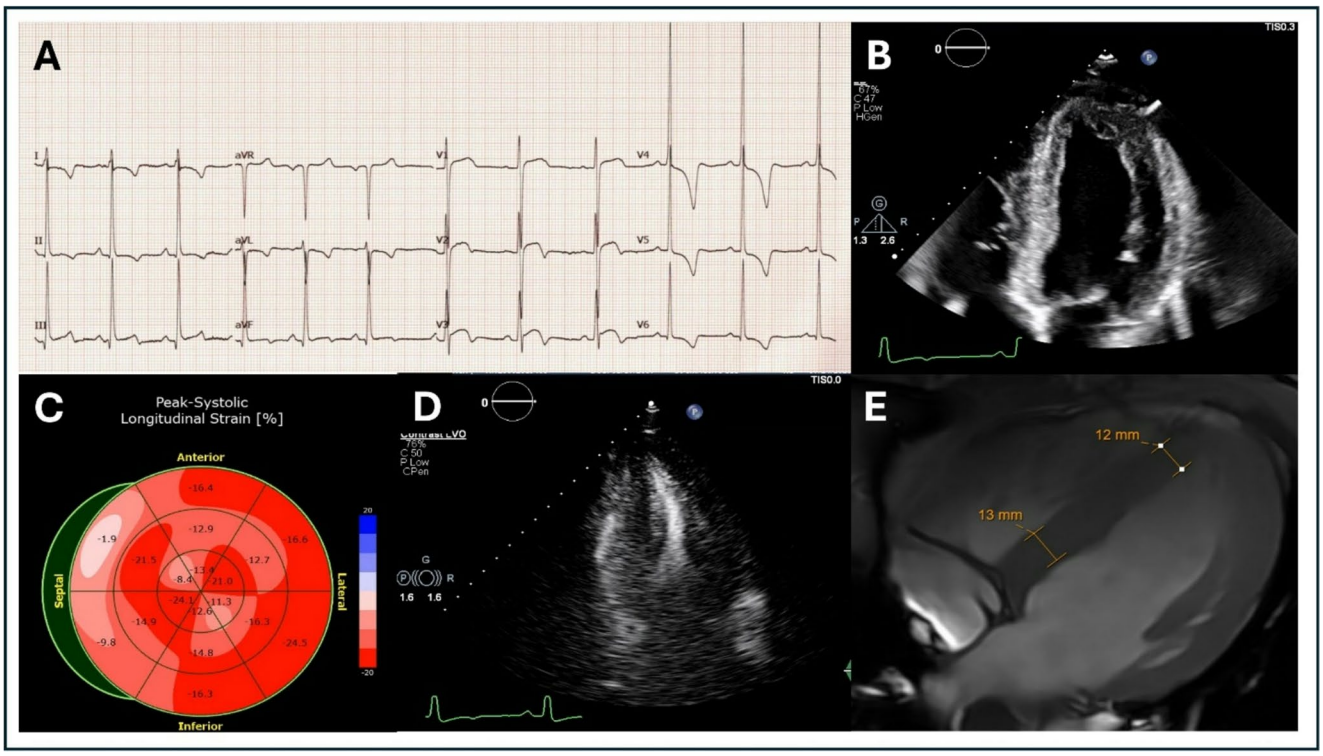

Fig. 2 The cardiac testing of an 18-year-old male athlete shows concerning findings suspicious for apical hypertrophic cardiomyopathy. The maximal wall thickness does not meet the generally accepted diagnostic criteria of 15mm however would meet criteria for relative apical HCM. Panel A is the abnormal ECG with diffuse T wave inversions. Panel B is an apical four chamber, left ventricle focused echocardiogram showing lack of apical tapering. Panel C show abnormal regional strain in the septal wall and apex. Panel D is a contrast enhance echocardiogram image obtained in the apical two chamber view showing the end systolic cavity and near obliteration of the apex. Panel E is the corresponding cardiac MRI showing borderline hypertrophy of the basal septal wall and increased wall thickness of the apex

abnormalities favors pathologic challenges. A valuable tool for distinguishing EICR from cardiomyopathy is the assessment of left ventricular contractile reserve with exercise testing. In studies examining contractile reserve in athletes and patients with dilated cardiomyopathy (DCM) with exercise echocardiography, 96% of athletes compared to 23% of DCM patients achieved an increased in LVEF > 11%. Additionally, achieving an absolute LVEF > 63% was seen in 92% of athletes compared to 17% of DCM patients [13]. A separate study using cardiac CMR found similar improvement in contractile reserve [15]. In practice, an increase in LVEF ≥ 10% has a low likelihood of pathology and should be reassuring. Left ventricular strain is often normal though much like LVEF, can be mildly reduced in the absence of pathology, though should raise suspicion for underlying disease in conjunction with additional abnormalities. The accepted value for global longitudinal strain (GLS) is < −17% but can vary among vendors.

Left ventricular diastolic function can become supranormal in endurance athletes with increases in early filling relative to atrial filling resulting in high E/A ratio. Tissue velocities are also commonly found to be elevated. In the presence of mildly reduced LVEF or increased left ventricular wall thickness, normal diastolic function can support EICR; however, it does not exclude the possibility of pathology. In a study of athletes with hypertrophic cardiomyopathy, 66.7% had septal E' of ≥ 0.09 m/s and 93.3% had lateral E' ≥ 0.09 m/s, and all athletes with concentric LVH pattern had average E/E' < 12 [8]. The finding of reduced mitral annular tissue velocities and abnormal average E/E'>12 should raise concern for pathology. Reduced septal E' or lateral E' < 0.07 m/s would be very unusual for an athlete and greatly favors a pathologic ventricle.

Another important left ventricular physiologic adaptation that can be present in athletes and mistaken for pathology is the presence of excessive trabeculations. The term.

"excessive trabeculation" aims to replace the historic "noncompaction" and its association with cardiomyopathy given the variation of trabeculation within the population and higher prevalence in particular groups such as athletes and pregnant women [16]. An increase in left ventricular trabeculation stems from increased preload and higher cardiac output states. The generally accepted criteria for excessive trabeculation by echocardiogram are those published by Jenni et al. [17]. The criteria include the presence of 2-layered myocardium with a ratio of trabecular to compact

myocardium > 2:1 measured in end-systole in the short axis view. In a study by Sharma et al. of 1146 athlete echocardiograms, they found that athletes had a higher prevalence of increased LV trabeculation than non-athlete controls (18.3% vs. 7.0%) and that 8.1% of athletes met criteria for left ventricular noncompaction [18]. The presence of myocardial abnormalities such as reduced systolic function or abnormal diastolic function with excessive trabeculation may suggest pathologic adaptation and should undergo further evaluation.

The Right Ventricle

The right ventricle (RV) can undergo similar physiologic adaptations to the left ventricle; however, this is seen primarily as right ventricular dilation and not hypertrophy. These changes are typically absent in athletes performing primarily strength training and more likely in endurance athletes such as rowers and cyclists. We know from prior studies that about half of endurance athletes have right ventricular chamber dilation [3]. Additional predictors of RV dilation include male gender, age, level of training, and duration of training [19, 20]. Several important measurements should be obtained in the standard manner described by the American Society of Echocardiography's recent guidelines [21]: right ventricular outflow tract (RVOT) parasternal long axis (PLAX) diameter, RVOT short axis (SAX) diameter, RV basal and mid cavity diameters, end diastolic area, and end systolic area.

Despite right ventricular dilation and remodeling, right ventricular systolic function typically remains preserved. Standard assessment with tricuspid annular plane systolic excursion (TAPSE) and systolic velocity (s') remain valid in the athlete population. Evaluation of additional systolic function parameters such as fractional area of change (FAC) in athletes in a systematic review found an average FAC of 35% in endurance athletes with a lower cutoff value of 32%, relative to the published normal value of 40%. Athletes primarily participating in strength training had a mean FAC of 41% though with a similar lower cutoff value of 32%. When examining right ventricular ejection fraction (RVEF) with cardiac MRI in this athlete cohort, the mean RVEF was 54% with a range of 52–57% [19]. Right ventricular strain has also been evaluated in athletes and shown to have regional reduction in the basal segments.

Right ventricular dilation should occur in conjunction with and to a similar degree as left ventricular dilation in the setting of exercise induced cardiac remodeling. The left ventricular size can be used as a control for the RV size with an expected RV: LV ratio of less than one. A pathologic cause of disproportionately dilated right ventricle is arrhythmogenic right ventricular cardiomyopathy (ARVC) [22]. The diagnostic criteria for ARVC have evolved since the original 1994 Task Force criteria and 2010 Revised Task Force criteria to the more recent 2020 International Criteria to reflect advancement in cardiac imaging techniques and growing phenotype involving left ventricular cardiomyopathy. The criteria remain categorized by cardiac imaging, tissue characterization, repolarization abnormalities, depolarization abnormalities, arrhythmias, and family history [23, 24]. One of the notable changes from the 2010 to the 2020 criteria is an increase in the cutoff for indexed right ventricular end diastolic volume in women from ≥ 90 mL/m^2 to > 112 mL/m^2 and for men from ≥ 100 mL/m^2 to > 121 mL/m^2. Newly included is a reference cutoff for athletes of > 130 mL/m^2. Echocardiography remains the initial imaging modality for assessment of suspected cardiomyopathy, though subsequent cardiac MRI is appropriate and necessary for further right ventricular functional assessment and tissue characterization. This can help measure RV compared with LV volumes and exclude the presence of myocardial scar which should be absent in athletes with physiologic RV enlargement.

The Left and Right Atria

Both the left and right atria are subject to remodeling with enlargement in the setting of strength and endurance training. Studies examining changes in size have shown greater increases in left atrial diameters in endurance athletes compared to strength athletes and both greater than sedentary controls. In assessing left atrial strain patterns in athletes, a recent study examined 111 elite athletes and found no difference in left atrial reservoir strain (LASr) or left atrial conduit strain (LAScd) compared to the non-athlete matched cohort. However, left atrial contraction strain was reduced in athletes compared to the control group [25]. The assessment and understanding of left atrial physiological changes remain an important endeavor, especially with the occurrence of atrial fibrillation in healthy athletes. It has been observed that a U-shaped curve exists between atrial fibrillation and exercise and that excessive training may lead to myocardial and left atrial inflammation and fibrosis, serving as a substrate for atrial fibrillation[26].

Valvular Structures

Standard assessment of the valvular structures with 2D echocardiography and color Doppler to identify any regurgitant or stenotic valvular disease should be performed. Trace and mild regurgitant lesions can be seen in athletic hearts similar

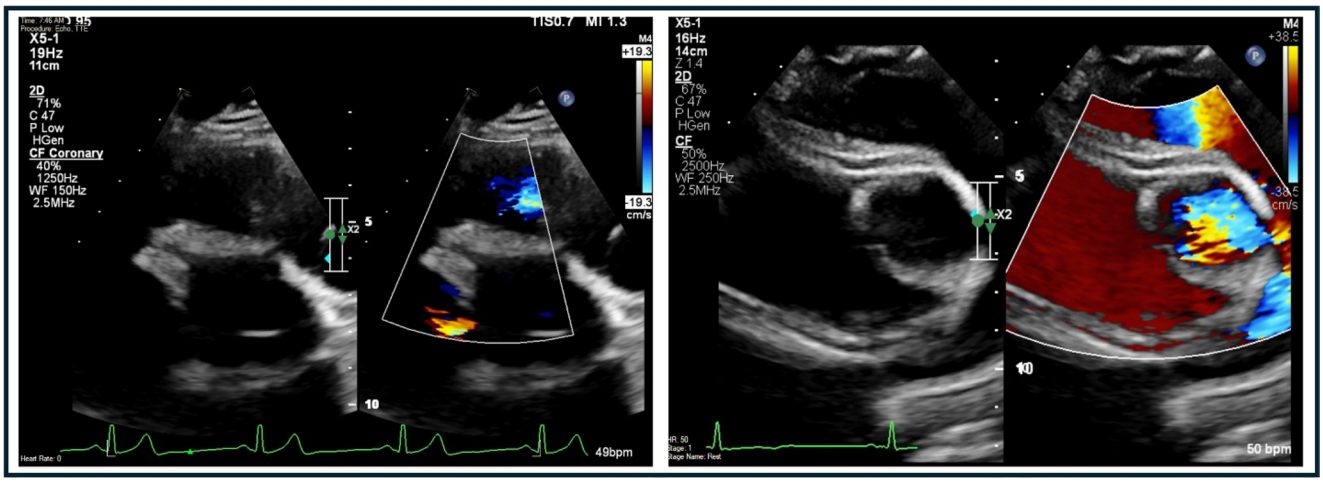

Fig. 3 The echocardiogram images were obtained in the parasternal short axis view utilizing 2D color compare. The image on the left is that of the right coronary artery and its origin from the right coronary sinus. The image on the right displays an anomalous right coronary artery which takes an inter-arterial course and originates from the lest coronary sinus

to the general population in the absence of pathology. Moderate and severe regurgitation should prompt further assessment to identify the etiology. Severe aortic valve stenosis can also lead to hypertrophy that overlaps with physiologic adaptation. Identifiable valvular abnormalities include bicuspid aortic valve and mitral valve prolapse, among others. Left and right ventricular remodeling, hypertrophy or dilation, may occur in the setting of exercise induced cardiac remodeling and valvular abnormalities as previously described. Therefore, detailed assessment and determination of impact is crucial to distinguish the two. Any identified hypertrophy or dilation should be commensurate with the degree of valve disease and may require review of the duration of valve disease and prior imaging studies.

The Coronary Arteries

The origins of the coronary arteries should be assessed when performing an echocardiogram on an athlete to determine anomalous origins that require further imaging. These images can be obtained in the parasternal short axis view at or above the level of the aortic valve. The origins of the right and left coronary arteries can be difficult to visualize in the same plane, so dedicated acquisition of each is often required. The proximal segments of the coronary arteries are typically surrounded by epicardial adipose tissue which aids in their visualization. These segments must be followed to the sinus to confirm their proper origin. The arteries should be examined with 2D echocardiography as well as color Doppler with verification of diastolic flow at a reduced Nyquist limit. This requires sonographer expertise and practice. An example of normal origin and anomalous origin of the right coronary artery are shown in Fig. 3.

The Aorta

The aortic root and proximal ascending aorta are readily assessed with 2D echocardiography and color flow Doppler. The American Society of Echocardiography recommends measuring from leading-edge to leading-edge at the end of diastole [9]. The dimensions of these segments of the aorta should be interpreted with age adjusted Z scores or indexed to body surface and/or height. The aortic dimensions of young athletes fall within the normal ranges of the general population despite the extremes of weight and height that can be encountered in athletes. While a relationship between aortic dimensions and body size exists, there are still limits to this relationship. In general, absolute values for the ascending aorta ≥ 40 mm in men and ≥ 34 mm in women are abnormal and should require detailed history and physical examination and further diagnostic evaluation. This data comes from several studies evaluating aortic sizes in thousands of athletes and one study which specifically examined professional basketball players and found that only 4.6% had aortic root dimension of ≥ 40 mm and 1.3% had a maximum dimension of 42 mm [27–29]. Any aortic measurement that exceeds 42 mm should be considered pathologic and requires a workup.

Beyond assessing aortic dimension for possible aortopathy, an echocardiogram can be used to evaluate for coarctation of the aorta and prior dissections which can go undiagnosed. It has been shown that athletes with mild nonobstructive coarctation have greater changes in systolic blood pressure with exercise than matched controls [30].

Conclusions

Echocardiography remains the principal tool for the primary assessment of symptomatic athletes and the secondary assessment of athletes with abnormal pre-participation screening. The cardiac adaptations to athletic training can present as chamber dilation and hypertrophy but typically occur in the absence of additional abnormalities including global longitudinal strain and diastolic function. There have been several important updates in the study of apical hypertrophic cardiomyopathy, left ventricular trabeculations, and arrhythmogenic cardiomyopathies that impact the interpretation of athlete echocardiograms. In addition to these updates, it remains vital to account for the athlete's history, age, gender, race, and training which all factor into the interpretation of the echocardiogram. If there is concern for pathology, additional cardiovascular imaging with CT and MRI can be helpful in defining anatomy and assessing tissue character.

Key References

- Kim, J.H., et al., *Clinical Considerations for Competitive Sports Participation for Athletes With Cardiovascular Abnormalities: A Scientific Statement From the American Heart Association and American College of Cardiology.* J Am Coll Cardiol, 2025. **85**(10): p. 1059-1108.

  ○ Describes the physiologic adaptions to endurance and strength training. Provides guidance on evaluating athletes with cardiac conditions.

- Oxborough, D., et al., *Echocardiography in the cardiac assessment of young athletes: a 2025 guideline from the British Society of Echocardiography (endorsed by Cardiac Risk in the Young).* Echo Res Pract, 2025. **12**(1): p. 7.

  ○ Describes approach to athletes with abnormal pre-participation cardiac screening and the incorporation of echocardiography into the evaluation of the athlete.

- Baggish, A.L., et al., *Recommendations on the Use of Multimodality Cardiovascular Imaging in Young Adult Competitive Athletes: A Report from the American Society of Echocardiography in Collaboration with the Society of Cardiovascular Computed Tomography and the Society for Cardiovascular Magnetic Resonance.* J Am Soc Echocardiogr, 2020.**33**(5): p. 523-549.

  ○ Describes the importance of echocardiography in athletes and the role of cardiac CT and cardiac MRI for further evaluation of cardiac pathology.

Author Contributions JTF and MWM wrote the manuscript. JTF prepared the Tables and Figures. All authors reviewed the manuscript for content.

Funding No funding was provided for this publication.

Data Availability No datasets were generated or analysed during the current study.

Declarations

Human and Animal Rights and Informed Consent This article does not contain any studies with human or animal subjects performed by any of the authors.

Competing interests The authors declare no competing interests.

Open Access This article is licensed under a Creative Commons Attribution-NonCommercial-NoDerivatives 4.0 International License, which permits any non-commercial use, sharing, distribution and reproduction in any medium or format, as long as you give appropriate credit to the original author(s) and the source, provide a link to the Creative Commons licence, and indicate if you modified the licensed material. You do not have permission under this licence to share adapted material derived from this article or parts of it. The images or other third party material in this article are included in the article's Creative Commons licence, unless indicated otherwise in a credit line to the material. If material is not included in the article's Creative Commons licence and your intended use is not permitted by statutory regulation or exceeds the permitted use, you will need to obtain permission directly from the copyright holder. To view a copy of this licence, visit http://creativecommons.org/licenses/by-nc-nd/4.0/.

References

1. Kim, J.H., et al., *Clinical Considerations for Competitive Sports Participation for Athletes With Cardiovascular Abnormalities: A Scientific Statement From the American Heart Association and American College of Cardiology.* J Am Coll Cardiol, 2025. **85**(10): p. 1059–1108.
2. Doronina A, et al. The female athlete's heart: comparison of cardiac changes induced by different types of exercise training using 3D echocardiography. Biomed Res Int. 2018;2018:3561962.
3. Baggish AL, et al. Recommendations on the use of multimodality cardiovascular imaging in young adult competitive athletes: a report from the American Society of Echocardiography in collaboration with the Society of Cardiovascular Computed Tomography and the Society for Cardiovascular Magnetic Resonance. J Am Soc Echocardiogr. 2020;33(5):523–49.
4. Oxborough D, et al. Echocardiography in the cardiac assessment of young athletes: a 2025 guideline from the British Society of Echocardiography (endorsed by Cardiac Risk in the Young). Echo Res Pract. 2025;12(1):7.

5. Maron BJ. Structural features of the athlete heart as defined by echocardiography. J Am Coll Cardiol. 1986;7(1):190–203.
6. Hughes RK, et al. Improved diagnostic criteria for apical hypertrophic cardiomyopathy. JACC Cardiovasc Imaging. 2024;17(5):501–12.
7. Tso JV, et al. Association between race and maladaptive concentric left ventricular hypertrophy in American-style football athletes. Br J Sports Med. 2022;56(3):151–7.
8. Sheikh N, et al. Clinical profile of athletes with hypertrophic cardiomyopathy. Circ Cardiovasc Imaging. 2015;8(7):e003454.
9. Lang, R.M., et al., *Recommendations for cardiac chamber quantification by echocardiography in adults: an update from the American Society of Echocardiography and the European Association of Cardiovascular Imaging.* J Am Soc Echocardiogr, 2015. **28**(1): p. 1–39 e14.
10. Liang Y, et al. *Left ventricular spherical index is an independent predictor for clinical outcomes in patients with nonischemic dilated cardiomyopathy*. JACC Cardiovasc Imaging. 2019;12(8 Pt 1):1578–80.
11. Flanagan H, et al. *The athlete's heart: insights from echocardiography*. Echo Res Pract. 2023;10(1):15.
12. Arbab-Zadeh A, et al. *Cardiac remodeling in response to 1 year of intensive endurance training*. Circulation. 2014;130(24):2152–61.
13. Millar LM, et al. *Differentiation between athlete's heart and dilated cardiomyopathy in athletic individuals*. Heart. 2020;106(14):1059–65.
14. Fabian, A., et al., *Biventricular mechanical pattern of the athlete's heart: comprehensive characterization using three-dimensional echocardiography.* Eur J Prev Cardiol, 2022. **29**(12): p. 1594–1604.
15. Claessen, G., et al., *Abstract 15529: Exercise CMR to Differentiate Athlete's Heart From Early Stage Dilated Cardiomyopathy.* Circulation, 2016. **134**(suppl_1): p. A15529-A15529.
16. Petersen, S.E., et al., *Excessive Trabeculation of the Left Ventricle: JACC: Cardiovascular Imaging Expert Panel Paper.* JACC Cardiovasc Imaging, 2023. **16**(3): p. 408–425.
17. Jenni R, et al. *Echocardiographic and pathoanatomical characteristics of isolated left ventricular non-compaction: a step towards classification as a distinct cardiomyopathy.* Heart. 2001;86(6):666–71.
18. Gati S, et al. *Increased left ventricular trabeculation in highly trained athletes: do we need more stringent criteria for the diagnosis of left ventricular non-compaction in athletes?*. Heart. 2013;99(6):401–8.
19. D'Ascenzi F, et al. Normative reference values of right heart in competitive athletes: a systematic review and meta-analysis. J Am Soc Echocardiogr. 2017;30(9):845–858 e2.
20. D'Ascenzi, F., et al., *Diagnostic Differentiation Between Arrhythmogenic Cardiomyopathy and Athlete's Heart by Using Imaging.* JACC Cardiovasc Imaging, 2018. **11**(9): p. 1327–1339.
21. Mukherjee M, et al. Guidelines for the echocardiographic assessment of the right heart in adults and special considerations in pulmonary hypertension: recommendations from the American Society of Echocardiography. J Am Soc Echocardiogr. 2025;38(3):141–86.
22. Moccia E, et al. Arrhythmogenic cardiomyopathy and differential diagnosis with physiological right ventricular remodelling in athletes using cardiovascular magnetic resonance. Int J Cardiovasc Imaging. 2022;38(12):2723–32.
23. Corrado D, et al. Diagnosis of arrhythmogenic cardiomyopathy: the Padua criteria. Int J Cardiol. 2020;319:106–14.
24. Corrado, D., et al., *Evolving Diagnostic Criteria for Arrhythmogenic Cardiomyopathy.* J Am Heart Assoc, 2021. **10**(18): p. e021987.
25. Baptista Carvalho A, Mendes L. Atrial strain assessment in elite athletes: unveiling physiologic adaptation. Eur Heart J Cardiovasc Imaging. 2025. https://doi.org/10.1093/ehjci/jeae333.316.
26. La Gerche, A., et al., *The Athlete's Heart-Challenges and Controversies: JACC Focus Seminar 4/4.* J Am Coll Cardiol, 2022. **80**(14): p. 1346–1362.
27. Boraita A, et al. Reference values of aortic root in male and female White elite athletes according to sport. Circ Cardiovasc Imaging. 2016. https://doi.org/10.1161/CIRCIMAGING.116.005292.
28. Engel DJ, Schwartz A, Homma S. Athletic cardiac remodeling in US professional basketball players. JAMA Cardiol. 2016;1(1):80–7.
29. Iskandar A, Thompson PD. A meta-analysis of aortic root size in elite athletes. Circulation. 2013;127(7):791–8.
30. Egbe AC, Allison TG, Ammash NM. Mild coarctation of aorta is an independent risk factor for exercise-induced hypertension. Hypertension. 2019;74(6):1484–9.

Publisher's Note Springer Nature remains neutral with regard to jurisdictional claims in published maps and institutional affiliations.